



SCIENTIFIC REPORTS
INTERNATIONAL

Surgical treatment for cataracts and the condition of dry eye

WAHEED FAISAI BAJANAID

ISSN:2045-2322

@srijournal.com ✉ info@srijournal.com

Introduction:

Cataract surgery is one of the most common and successful ophthalmic procedures performed worldwide, offering significant improvements in visual acuity and quality of life for millions of individuals affected by cataracts. However, despite its efficacy, cataract surgery has been increasingly recognized as a potential precipitant or exacerbator of dry eye symptoms in a subset of patients (Davis, 2016).

Dry eye disease (DED) encompasses a range of illnesses that result in instability of the tear film, increased osmolarity, persistent inflammation, and abnormalities in the nerves responsible for sensation, all of which contribute to long-term dysfunction of the surface of the eye. Preexisting dry eye disease (DED) can create difficulties after cataract surgery, particularly when there is persistent inflammation, scarring, irregular eyelids, and reduced clarity of the eye's internal structures. Additionally, it is recognized that this condition deteriorates after cataract surgery, resulting in an increased likelihood of complications and impaired visual results. The likely cause of this is an elevation in inflammation, toxicity resulting from eye drops that contain preservatives such as benzalkonium chloride (BAK), and damage to the nerves in the cornea caused by incisions made near the limbus. In addition, phacoemulsification alone has been documented to result in a decrease in tear film breakdown time, tear meniscus height, and corneal sensitivity after the surgery (Donthineni, et al.2020).

The higher prevalence of DED is associated with aging, which is exactly the trend observed in cases of cataract. Therefore, it is not unusual to come into situations when we must handle both dry eye and cataract either at the same time or in a specific order. Understanding the multiple elements that determine the outcomes of cataract surgery in eyes with pre-existing dry eye disease (DED) is crucial for achieving satisfactory results. The correlation between cataract surgery and dry eye has attracted significant interest in recent years, as medical professionals and researchers strive to get a deeper understanding of the mechanisms that link these two conditions and devise methods to minimize their effects on patient outcomes. The precise cause of postoperative dry eye is intricate and involves multiple factors. These factors include changes in corneal nerve supply,

damage to the outer layer of the eye's surface, alterations in the dynamics of tear production, and inflammation resulting from surgical injury (Donthineni, et al. 2020).

Despite advances in surgical techniques and perioperative management, a subset of patients continues to experience persistent or worsening dry eye symptoms following cataract surgery, highlighting the need for further investigation into this phenomenon. Understanding the prevalence, risk factors, clinical manifestations, and management strategies associated with post-cataract surgery dry eye is essential for optimizing patient care and enhancing surgical outcomes (Naderi, et al.2020).

☒ **Etiology of cataract:**

Cataracts form as a result of the aggregation of proteins in the eye's lens, leading to opacity and disruption of visual acuity. Although age is the main determinant of cataract formation, there are various other factors that can heighten the risk or expedite the progression of cataracts. The factors can be broadly classified as environmental, behavioral, genetic, and medical factors (Gupta, et al.2014).

- Prolonged exposure to ultraviolet (UV) radiation from sunlight can cause damage to the proteins in the lens, leading to the development of cataracts. Moreover, being exposed to specific chemicals or poisons, such as tobacco smoke, air pollution, and heavy metals, might heighten the likelihood of developing cataracts.
- Cataract formation may be influenced by lifestyle factors, particularly inadequate nutrition, namely a diet deficient in antioxidants such vitamins C and E. Obesity and diseases such as diabetes might heighten the likelihood of developing cataracts, most likely because of their influence on metabolism and systemic inflammation (Braakhuis, et al.2019).
- Genetic factors can make individuals more likely to develop cataracts, as specific genetic mutations or variations can affect the structure and function of the proteins in the lens. These hereditary inclinations may be present in families and play a role in the onset of cataracts at a younger age.

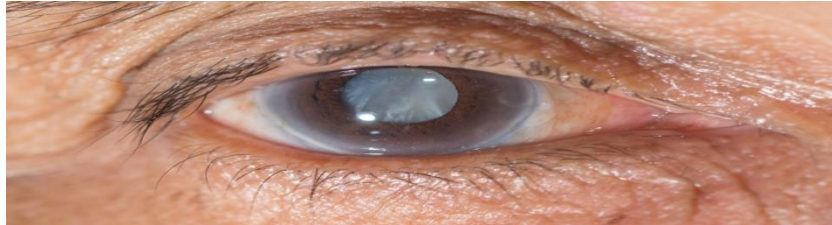
- Several medical problems and medications might potentially heighten the susceptibility to cataracts. These factors encompass extended utilization of corticosteroid drugs, radiation treatment targeting the head or neck area, and certain systemic ailments like hypertension and metabolic problems (Gupta, et al.2014).

☒ **The potential link between cataract surgery and exacerbation or development of dry eye symptoms:**

There is growing recognition of the potential link between cataract surgery and the exacerbation or development of dry eye symptoms in some patients. This connection can be attributed to various anatomical and physiological changes that occur during the surgical process, impacting the ocular surface and tear film dynamics (Naderi, et al.2020).

- **Disruption of the corneal nerves:** One of the key anatomical changes during cataract surgery is the incision and manipulation of the ocular tissues, particularly the cornea. The creation of corneal incisions and the use of instruments within the anterior chamber can disrupt the corneal nerves, which play a crucial role in regulating tear production and maintaining corneal sensitivity. This disruption of corneal innervation can lead to a decrease in tear film stability and production, contributing to dry eye symptoms postoperatively.
- **Changes in tear film dynamics:** changes in tear film dynamics can occur as a result of cataract surgery. The manipulation of the eye during surgery, along with the use of intraocular fluids and medications, can alter the composition and distribution of the tear film. This disruption in tear film dynamics may result in decreased tear film stability and inadequate lubrication of the ocular surface, leading to symptoms of dryness, irritation, and discomfort (Donthineni, et al.2020).
- **Alterations in ocular surface anatomy:** alterations in ocular surface anatomy following cataract surgery can contribute to dry eye symptoms. The removal of the cataractous lens and its replacement with an intraocular lens (IOL) can affect the balance of tear production and distribution across the ocular surface. Changes in the anterior chamber depth, corneal

curvature, and IOL position can influence tear film dynamics and ocular surface wetting, potentially leading to dry eye symptoms postoperatively (Naderi, et al.2020).



☒ **Clinical Assessment:**

Several methods are commonly used by clinicians to evaluate dry eye symptoms and severity for this patient population:

- **Subjective Symptom Questionnaires:** Patient-reported outcome measures, such as the Ocular Surface Disease Index (OSDI) or the Dry Eye Questionnaire (DEQ), are frequently used to assess the severity of dry eye symptoms. These questionnaires include questions about symptoms such as ocular discomfort, dryness, burning, itching, and visual disturbances. Patients rate the frequency and severity of their symptoms, providing valuable information about their subjective experience of dry eye (Garg, et al.2020).
- **Tear Film Osmolarity Measurements:** Tear film osmolarity is a quantitative measure of tear film stability and can indicate ocular surface health. Elevated tear film osmolarity is associated with tear film instability and ocular surface inflammation, both of which are characteristic features of dry eye syndrome. Osmolarity testing, such as the TearLab Osmolarity System, provides objective data on tear film osmolarity levels, aiding in the diagnosis and monitoring of dry eye in cataract surgery patients (Potvin, et al.2015).
- **Ocular Surface Staining:** Vital dyes, such as fluorescein and lissamine green, are used to assess ocular surface integrity and detect areas of epithelial damage or irregularities. These dyes are instilled into the eye and visualized under a blue light or slit lamp microscope. Ocular surface staining can reveal corneal and conjunctival epithelial defects, punctate epithelial erosions, and other signs of ocular surface damage associated with dry eye disease (Wu, et al.2022).

- **Tear Breakup Time (TBUT):** Tear breakup time is a simple and noninvasive test used to evaluate tear film stability. During TBUT assessment, a fluorescein dye is instilled into the eye, and the clinician observes the time it takes for dry spots or irregularities to appear in the tear film after a blink. A shorter TBUT is indicative of tear film instability and may suggest underlying dry eye pathology (Wu, et al.2022).
- **Schirmer's Test:** Although less commonly used in clinical practice, Schirmer's test measures tear production by quantifying the amount of tears produced over a specified period. This test involves placing filter paper strips in the lower eyelid to absorb tears. Reduced tear production, as indicated by lower Schirmer scores, may suggest aqueous deficiency and contribute to dry eye symptoms in cataract surgery patients (Wu, et al.2022).

☒ **Risk Factors:**

Multiple variables can influence the occurrence or exacerbation of dry eye symptoms after undergoing cataract surgery:

- **Patient Demographics:** Demographic characteristics, such as advanced age and female sex, are linked to a higher susceptibility to dry eye syndrome. Elderly individuals may experience a decline in tear production and a decrease in the integrity of their tear film, making them more susceptible to experiencing dry eye symptoms after undergoing cataract surgery. Likewise, fluctuations in hormones in women, especially during menopause, can impact the production of tears and worsen symptoms of dry eye (Donthineni, et al.2023).
- **Pre-existing Dry Eye Disease:** Patients who already have dry eye disease are more likely to experience worsening or continued symptoms after undergoing cataract surgery. The presence of dry eye can exacerbate chronic inflammation of the ocular surface, instability of the tear film, and damage to the corneal epithelium. These conditions can be further intensified by the surgical trauma and drugs used after cataract surgery.
- **Surgical Technique:** The surgical method used during cataract surgery can affect the occurrence of dry eye symptoms after the operation. Variables such as the dimensions and placement of the incision, as well as its depth, along with the length of the surgical procedure,

might impact the degree of disturbance to the ocular surface and the harm caused to the corneal nerves. Minimally invasive procedures, such as microincision cataract surgery (MICS), can cause less harm to the surface of the eye and lower the chances of experiencing dry eye symptoms when compared to older approaches (Donthineni, et al.2023).

- **Intraocular Lens (IOL) Selection:** The kind of intraocular lens (IOL) used in cataract surgery can impact the dynamics of the tear film and the health of the ocular surface. Some intraocular lenses (IOLs), such as multifocal or extended depth of focus (EDOF) lenses, can cause higher-order aberrations or affect contrast sensitivity. This might result in visual disturbances and dry eye complaints for certain patients. In addition, hydrophobic acrylic intraocular lenses (IOLs) may lead to higher levels of postoperative inflammation and surface epithelial alterations as compared to hydrophilic IOLs (Lapp, et al.2023).
- **Postoperative Medications:** The application of corticosteroids, nonsteroidal anti-inflammatory drugs (NSAIDs), and antibacterial eye drops after cataract surgery can affect the stability of the tear film and the health of the surface of the eye. Corticosteroids, although they are beneficial in lowering inflammation after surgery, can decrease tear production and worsen symptoms of dry eye, especially when used for a long period of time. Nonsteroidal anti-inflammatory drugs (NSAIDs) can also cause irritation of the surface of the eye and weaken the protective layer of tears, particularly in individuals who already have dry eye disease (Ashena, et al.2021).

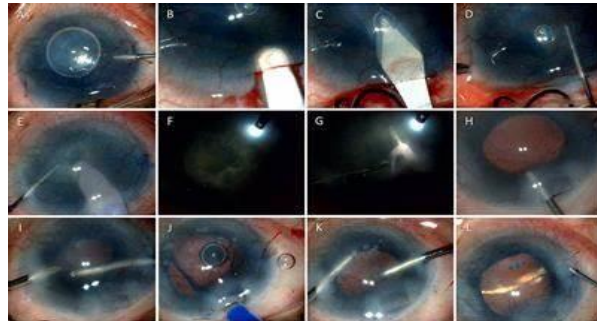
☒ **Surgical Techniques and Modifications:**

Several surgical approaches or adjustments to promote ocular surface health and tear film stability can be used to decrease dry eye symptoms during or after cataract surgery:

- **Use of Preservative-Free Topical Drugs:** Using topical drugs free of preservatives, such as lubricating eye drops, antibiotics, and anti-inflammatory medicines, might reduce the likelihood of ocular surface irritation and the chance of worsening dry eye symptoms after surgery. Preservatives like benzalkonium chloride (BAK), which are frequently used in eye

drops, have the potential to be cytotoxic to the ocular surface and exacerbate the symptoms of dry eye in those who are vulnerable (Venkateswaran, et al.2022).

- **Minimally Invasive Techniques:** The goal of minimally invasive cataract surgery techniques, including femtosecond laser-assisted cataract surgery (FLACS) or microincision cataract surgery (MICS), is to minimize corneal nerve disturbance and surgical stress to the ocular surface. More rapid visual recovery and less postoperative inflammation may be achieved by smaller incision sizes and more precise tissue manipulation in MICS and FLACS procedures. This could improve ocular surface health and lower the incidence of dry eye complaints.
- **Optimized Incision Placement:** During cataract surgery, careful consideration of the incision's size and location can reduce the risk of damaging the corneal nerve and maintain the integrity of the ocular surface. Clear or limbal corneal incisions made far from the corneal nerve plexus may preserve corneal sensitivity after surgery and lower the incidence of neurotrophic dry eye. A watertight wound closure can also assist keep the ocular surface hydrated and stop too much tear evaporation (Venkateswaran, et al.2022).
- **Intraoperative Management of Ocular Surface Hydration:** Reducing dry eye symptoms during cataract surgery requires maintaining appropriate ocular surface hydration throughout the surgical process. Techniques like the intraoperative use of viscoelastic agents or balanced salt solution (BSS) can assist keep the corneal endothelium hydrated and stop the ocular surface from drying up. Additionally, to prevent the cornea and conjunctiva from drying out during surgery, ocular lubricants or viscoelastic devices can be used during phacoemulsification (Venkateswaran, et al.2022).



☒ Postoperative Management:

Postoperative management of dry eye symptoms in patients undergoing cataract surgery involves a combination of preventive measures and targeted interventions to optimize ocular surface health and promote healing:

- **Preservative-Free Lubricating Eye Drops:** Lubricating eye drops are commonly used to alleviate dryness and discomfort following cataract surgery. Preservative-free formulations are preferred, as they minimize the risk of ocular surface toxicity and allergic reactions. Patients are typically instructed to use lubricating drops frequently throughout the day to maintain ocular surface hydration and alleviate symptoms of dryness and irritation (Kanclerz,& Tuuminen, 2022).
- **Anti-Inflammatory Medications:** Topical corticosteroids and nonsteroidal anti-inflammatory drugs (NSAIDs) are often prescribed following cataract surgery to reduce inflammation and promote healing. These medications can help alleviate symptoms of ocular surface irritation and minimize the risk of postoperative complications such as cystoid macular edema (CME). Short-term use of corticosteroids may be necessary to control inflammation, but prolonged use should be avoided to prevent ocular surface toxicity and exacerbation of dry eye symptoms.
- **Punctal Plugs:** Punctal plugs are small, biocompatible devices inserted into the puncta (tear ducts) to block tear drainage and increase tear retention on the ocular surface. In patients with severe dry eye or aqueous deficiency, punctal plugs can help preserve tears and improve ocular surface lubrication following cataract surgery. Temporary or dissolvable plugs may be initially

- used to assess their efficacy before considering permanent plugs (Kanclerz,& Tuuminen, 2022).
- **Artificial Tears Ointments:** In cases of persistent or severe dry eye symptoms, especially overnight or during periods of prolonged eye closure (e.g., sleep), the use of lubricating ointments or gels may be beneficial. These thicker formulations provide longer-lasting lubrication and protection to the ocular surface, helping to prevent nighttime dryness and discomfort.
- **Moisture Chamber Goggles:** Moisture chamber goggles or glasses with side shields can help create a humid microenvironment around the eyes, reducing evaporative tear loss and alleviating symptoms of dryness and irritation. These protective eyewear options are particularly useful in environments with low humidity or high airflow, such as air-conditioned or heated spaces (Kanclerz,& Tuuminen, 2022).
- **Adjunctive Therapies:** Additional adjunctive therapies for managing dry eye symptoms post-cataract surgery may include omega-3 fatty acid supplements, lid hygiene practices, warm compresses, and eyelid massage to promote meibomian gland function and improve tear film quality. These therapies can help address the underlying causes of dry eye and enhance the effectiveness of other treatment modalities.

☒ **Long-term Follow-up after cataract surgery:**

Long-term follow-up after cataract surgery is essential to monitor patients' visual outcomes, assess the stability of surgical results, and detect potential complications or changes in ocular health over time. Here are some key aspects of long-term follow-up after cataract surgery:

- **Visual Acuity and Refraction:** Assessing visual acuity and refractive status is fundamental during long-term follow-up visits after cataract surgery. Monitoring visual acuity helps evaluate the effectiveness of the surgical procedure and detect any changes in visual function over time. Refractive assessment allows for optimization of visual outcomes and may indicate the need for adjunctive treatments such as glasses or contact lenses (Khoramnia, et al.2022).
- **Ocular Health Examination:** Regular ocular health examinations are conducted to evaluate the integrity of the ocular structures and detect any signs of postoperative complications such

as posterior capsule opacification (PCO), glaucoma, retinal pathology, or corneal abnormalities. Slit-lamp biomicroscopy and dilated fundus examination are commonly performed to assess the anterior and posterior segments of the eye.

- **Intraocular Pressure (IOP) Monitoring:** Measurement of intraocular pressure is crucial for detecting and managing postoperative complications such as ocular hypertension or glaucoma. Elevated IOP may occur secondary to steroid use, inflammation, or underlying glaucomatous pathology and requires prompt intervention to prevent vision loss.
- **Evaluation of Intraocular Lens (IOL) Position and Stability:** Assessing the position and stability of the implanted IOL is important during long-term follow-up visits. Slit-lamp examination and specialized imaging techniques such as optical coherence tomography (OCT) or ultrasound biomicroscopy (UBM) can be used to evaluate IOL centration, tilt, and fixation within the capsular bag (Moustafa, et al.2019).
- **Monitoring for Posterior Capsule Opacification (PCO):** PCO, also known as secondary cataract, is a common complication following cataract surgery due to residual lens epithelial cell proliferation on the posterior capsule. Regular assessment for PCO involves visual acuity testing, slit-lamp examination, and retroillumination photography to detect any signs of visual impairment or opacification of the posterior capsule.
- **Assessment of Dry Eye Symptoms:** Monitoring for dry eye symptoms and ocular surface health is important during long-term follow-up after cataract surgery, particularly in patients with pre-existing dry eye disease or those at risk for developing dry eye symptoms postoperatively. Evaluating tear film stability, tear production, ocular surface staining, and patient-reported symptoms can help guide management strategies and optimize patient comfort (Khoramnia, et al.2022).
- **Patient Education and Counseling:** Providing ongoing patient education and counseling about postoperative care, potential complications, and the importance of regular follow-up visits is essential for ensuring optimal outcomes and patient satisfaction after cataract surgery. Empowering patients with knowledge about their eye health and encouraging adherence to treatment recommendations can help minimize the risk of complications and promote long-term ocular wellness (Moustafa, et al.2019).

Conclusion:

Cataract surgery is a highly effective technique designed to improve vision and enhance quality of life, and has been increasingly linked to the occurrence or worsening of dry eye symptoms in specific people. The relationship between cataract surgery and dry eye involves intricate anatomical and physiological transformations, such as the disturbance of corneal nerves, modifications in tear film movement, and abnormalities in the structure of the ocular surface. Although there have been improvements in surgical procedures and perioperative management, a specific group of patients still suffer from ongoing or increasing dry eye symptoms after surgery. Gaining knowledge about the frequency, factors that increase the likelihood, symptoms, and approaches to treating dry eye after cataract surgery is essential for improving patient treatment and achieving better surgical results. Multiple techniques are accessible for evaluating the symptoms and intensity of dry eye, such as subjective questionnaires to assess symptoms, measuring tear film osmolarity, examining the staining of the ocular surface, determining tear breakup time, and doing Schirmer's test.

References:

- Ashena, Z., Nanavaty, M. A., Bardan, A. S., Thaker, R., & Bascaran, L. (2021). Prophylactic use of nonsteroidal anti-inflammatory drugs after cataract surgery and corneal melt. *Journal of current ophthalmology*, 33(4), 485-491.
- Braakhuis, A. J., Donaldson, C. I., Lim, J. C., & Donaldson, P. J. (2019). Nutritional strategies to prevent lens cataract: current status and future strategies. *Nutrients*, 11(5), 1186.
- Davis, G. (2016). The evolution of cataract surgery. *Missouri medicine*, 113(1), 58.
- Donthineni, P. R., Das, A. V., Shanbhag, S. S., & Basu, S. (2020). Cataract surgery in dry eye disease: visual outcomes and complications. *Frontiers in Medicine*, 7, 575834.
- Donthineni, P. R., Deshmukh, R., Ramamurthy, C., Sangwan, V. S., Mehta, J. S., & Basu, S. (2023). Management of cataract in dry eye disease: Preferred practice pattern guidelines. *Indian Journal of Ophthalmology*, 71(4), 1364-1372.
- Garg, P., Gupta, A., Tandon, N., & Raj, P. (2020). Dry eye disease after cataract surgery: study of its determinants and risk factors. *Turkish journal of ophthalmology*, 50(3), 133.
- Gupta, V. B., Rajagopala, M., & Ravishankar, B. (2014). Etiopathogenesis of cataract: an appraisal. *Indian journal of ophthalmology*, 62(2), 103-110.
- Kanclerz, P., & Tuuminen, R. (2022). Advancements in Postoperative Care after Cataract Surgery. *Journal of clinical medicine*, 11(11), 3162.
- Khoramnia, R., Auffarth, G., Łabuz, G., Pettit, G., & Suryakumar, R. (2022). Refractive outcomes after cataract surgery. *Diagnostics*, 12(2), 243.
- Lapp, T., Wacker, K., Heinz, C., Maier, P., Eberwein, P., & Reinhard, T. (2023). Cataract surgery—indications, techniques, and intraocular lens selection. *Deutsches Ärzteblatt International*, 120(21-22), 377.
- Moustafa, G. A., Borkar, D. S., Borboli-Gerogiannis, S., Greenstein, S. H., Lorch, A. C., Vasan, R. A., & Kloek, C. E. (2019). Optimization of cataract surgery follow-up: a standard set of questions can predict unexpected management changes at postoperative week one. *Plos one*, 14(9), e0221243.
- Naderi, K., Gormley, J., & O'Brart, D. (2020). Cataract surgery and dry eye disease: a review. *European Journal of Ophthalmology*, 30(5), 840-855.
- Potvin, R., Makari, S., & Rapuano, C. J. (2015). Tear film osmolarity and dry eye disease: a review of the literature. *Clinical ophthalmology*, 2039-2047.
- Venkateswaran, N., Luna, R. D., & Gupta, P. K. (2022). Ocular surface optimization before cataract surgery. *Saudi Journal of Ophthalmology*, 36(2), 142-148.
- Wu, Y., Wang, C., Wang, X., Mou, Y., Yuan, K., Huang, X., & Jin, X. (2022). Advances in dry eye disease examination techniques. *Frontiers in Medicine*, 8, 826530.